

# Hypochlorous acid gel technology—Its impact on postprocedure treatment and scar prevention

Michael H. Gold MD, FAAD<sup>1,2,3,4</sup>  | Anneke Andriessen PhD<sup>5</sup>  | Steven H. Dayan MD<sup>6</sup> |  
Sabrina G. Fabi MD<sup>7</sup> | Z. Paul Lorenc MD, FACS<sup>8,9</sup> | Meagan-Helen Henderson Berg  
MDCM<sup>10</sup>

<sup>1</sup>Gold Skin Care Center, Nashville, TN, USA

<sup>2</sup>Tennessee Clinical Research Center, Nashville, TN, USA

<sup>3</sup>Vanderbilt University School of Nursing, Nashville, TN, USA

<sup>4</sup>School of Medicine, Meharry Medical College, Nashville, TN, USA

<sup>5</sup>Andriessen Consultants & Radboud UMC, Nijmegen, The Netherlands

<sup>6</sup>Department of Otolaryngology, Division of Facial Plastic and Reconstructive Surgery, University of Illinois, Chicago, IL, USA

<sup>7</sup>Cosmetic Laser Dermatology, San Diego, CA, USA

<sup>8</sup>Lorenc Aesthetic Plastic Surgery Center, New York, NY, USA

<sup>9</sup>Department of Plastic Surgery, Lenox Hill Hospital, New York, NY, USA

<sup>10</sup>Faculty of Medicine, McGill University, Montreal, Canada

## Correspondence

Dr Anneke Andriessen, Zwenkgras 25, 6581 RK Malden, The Netherlands.  
Email: anneke.a@tiscali.nl

## Funding information

IntraDerm Pharmaceuticals, Grant/Award Number: supported literature research with an educational grant

## Summary

**Background:** A pre- and postprocedure regime aimed at prevention of infection, reduction of inflammation and risk of scarring, is to enable optimal outcomes.

**Objectives:** The role of a hypochlorous acid containing spray and translucent scar gel formulation that combines modified silicon oil with hypochlorous acid, was explored for pre- and postprocedure treatment and scar management.

**Methods:** For this purpose a literature review was conducted to explore the value of the technology used in pre- and postprocedural regimes. A panel of dermatologists and plastic surgeons who practice in the United States discussed the summarized search results, taking into account their current clinical practice. A nominal group process for consensus was used, followed by online reviews of the manuscript.

**Results:** Based on panel discussions, consensus was reached regarding clinical recommendations given for postprocedure treatment and scar management. The hypochlorous acid products are produced with electrolysis and are classified among biocidal substances. The technology has demonstrated efficacy and safety for pre- and postprocedure use. The safety of hypochlorous solution use demonstrated to be comparable to that of standard local antiseptics. Small studies demonstrated better results with the scar gel compared to silicone gel regarding the appearance of hypertrophic and keloid scars, relief of associated pruritus and pain.

**Conclusions:** A postprocedure regime using this technology, aimed at preventing infection, reducing inflammation, and promoting healing is proposed to have benefits over current regimes as it appears to be effective, safe, and well tolerated.

## KEYWORDS

hypochlorous acid technology, postprocedure care, scar management

## 1 | INTRODUCTION

Clinician concerns over pre- and postprocedure care and scar management are at the forefront. They are balancing antiseptic properties and cytotoxicity with severity of colonization to assure a proper healing environment and enhance outcomes. Our immune system

naturally produces a compound called hypochlorous acid (HOCL) to eradicate bacteria and other invading pathogens within the body. This compound has also shown antipruritic and anti-inflammatory effects.<sup>1,2</sup> A HOCL containing spray or super-oxidized solution for cleansing, irrigation, and disinfection of surgical sites (Alevicyn Dermal Spray) may decrease the risk of infection and optimize surgical

outcomes.<sup>1,2</sup> The spray is used both for prepping the surgical site and for disinfection before surgical closure and then twice a day for 1 week for postprocedure care to enhance healing. There is also a translucent gel formulation that combines a modified silicon oil with HOCL for scar management (Celacyn) that can be used adjunctively with the dermal spray to improve the appearance of scars, manage itching and pain associated with scars. The HOCL gel is applied twice a day for 6–8 weeks. The HOCL solution with neutral pH has been considered a safe and effective biocide for skin and wound disinfection.<sup>1,2</sup> The principle of HOCL production is stabilization using an electrolytic or redox reaction of purified water and salt (NaCl), which is passed through anode and cathode chambers that are separated from a middle salt chamber by ionic membranes in redox equipment.<sup>1</sup> The super-oxidized technology has a neutral pH (5.2–7.8) and free available chlorine starting at 120 parts per million. While alkaline ionized water is considered to have a cleansing effect, the acid part has a strong biocidal effect.

We explored the role of HOCL containing spray and scar gel for preprocedure, postprocedure treatment, and scar management.

## 2 | METHODS

A literature review was conducted to explore the value of a pre-and postprocedural regime using HOCL technology. Databases searched were: EMBASE, MEDLINE, CINAHL, PubMed, and The Cochrane Library. Publications were on HOCL solution, spray, or scar gel and included in vitro and in vivo studies, randomized controlled trials, well-designed cohort, or case–control analytical studies and case reports published from January 1, 2005 up to June 1, 2016. Searches were prospectively limited to publications in the English language. Medical subject heading terms were used in various combinations in the literature search and included HOCL for wound and skin disinfection, wound healing, scar management and postprocedural treatment.

A panel of dermatologists and plastic surgeons who practice in the United States gathered for a one-day meeting in July 2016 in Las Vegas. Before the meeting, the panel members received the results of the literature review. A nominal group process for consensus was used. Based on panel discussions, consensus was reached

regarding clinical recommendations given for postprocedure treatment and scar management using HOCL technology. The manuscript was developed, reviewed by the panel members, and prepared for publication.

### 2.1 | Hypochlorous acid technology mode of action

A detailed analysis has revealed that the product works through several mechanisms (Table 1).<sup>1,2</sup> It seems to have an effect on all phases of healing. HOCL has been shown to be a potent antimicrobial, a fast acting antipruritic, exhibits anti-inflammatory properties, increases oxygenation (TcPO<sub>2</sub>) at wound sites, and breaks down biofilm.

Hypochlorous acid has demonstrated that it is potent and fast acting. It targets nonspecific biomolecules on bacterial cell membranes. Initial cell surface reactions to hypochlorous acid have been reported to occur in as little as 100 milliseconds. It is a highly reactive compound and upon reaction it is completely rendered neutral. Unlike antibiotics, the potency of HOCL is delivered with no specificity. HOCL damages the integrity of the bacterial cell membrane through increasing its permeability. In vitro tests of cytotoxicity and oxidative stress induced by HOCL compared to hydrogen peroxide on young, primary diploid—human dermal fibroblast cultures showed hydrogen peroxide to be significantly more cytotoxic than HOCL.<sup>2–5</sup>

In vitro, HOCL did not induce genotoxicity.<sup>2–5</sup> Thanks to its mechanism of action, HOCL has a broad spectrum of activity and has proved itself as an effective agent, even in the presence of biofilms.<sup>6–8</sup> HOCL attacks the microbe cell membrane by dissolving the protective membrane of the biofilm.<sup>6–8</sup> When tested for in vitro antimicrobial and antiviral activities, effectiveness of HOCL solution at eradicating *Staphylococcus aureus*, *Escherichia coli*, *Pseudomonas aeruginosa*, *Salmonella typhi*, and *Candida albicans* in pure culture was demonstrated.<sup>6</sup>

Hypochlorous acid's anti-inflammatory effect comes from the effect it has on mast cells. Data suggests that neutral pH-SOS (super-oxidized solution) acts like a mast cell membrane stabilizing inhibitor.

The cell machinery for granule secretion acts without altering the signal transduction pathways induced by IgE-antigen receptor cross-linking.<sup>4</sup> The antipruritic effects were studied on mild-to-moderate atopic patients and showed improvement as early as day 1.<sup>7</sup>

**TABLE 1** In vitro and in vivo studies

No	Author/publication	Country	Title of study
1	Landa-Solis C, González-Espinosa D, Guzmán-Soriano B, et al. <i>J Hosp Infect.</i> 2005;61(4):291-299 <sup>1</sup>	Mexico	Microcyn: a novel super-oxidized water with neutral pH and disinfectant activity
2	Le Duc Q, Breetveld M, Middelkoop E, et al. <i>British Journal of Dermatology</i> 2007;(3):1365-2133. <sup>3</sup>	The Netherlands	A cytotoxic analysis of antiseptic medication on skin substitutes and autograft
3	Medina-Tamayo J, Sánchez-Miranda E, Balleza-Tapia H, et al. <i>Int Immunopharmacol.</i> 2007 Aug;7(8):1013-24. <sup>4</sup>	Mexico	Super-oxidized solution inhibits IgE-antigen-induced degranulation and cytokine release in mast cells
4	González-Espinosa D, Pérez-Romano L, Guzmán-Soriano B, et al. <i>Int Wound J.</i> 2007;4(3):241-50 <sup>5</sup>	Mexico	Effects of pH-neutral, super-oxidized solution on human dermal fibroblasts in vitro
5	Sun JL, Zhang SK, Chen JY, Han BZ <i>Can J Microbiol.</i> 2012;58:448–54. <sup>25</sup>	Canada	Efficacy of acidic and basic electrolyzed water in eradicating <i>Staphylococcus aureus</i> biofilm.

**TABLE 2** Clinical studies

No	Author	Country	Title of study
1	Bongiovanni CM. <i>Journal for Vascular Ultrasound</i> . 2006; 30(4):215-218. <sup>8</sup>	USA	Nonsurgical Management of Chronic Wounds in Patients with Diabetes
2	Dalla Paola L, Brocco E, Senesi A, et al. <i>WOUNDS</i> 2006;18(9):262-270. <sup>9</sup>	Italy	Super-Oxidized Solution (SOS) Therapy for Infected Diabetic Foot Ulcers
3	Goretti C, Mazzurco S, Ambrosini Nobili L, et al. <i>Lower Extremity Wounds</i> 2007;6(11):22-27. <sup>10</sup>	Italy	Clinical Outcome of Wide Postsurgical lesions in the Infected Diabetic Foot Managed with 2 different local treatment regimes compared using Quasi Experimental Study Design: A preliminary comm.
4	Martinez de Jesus FR, Ramos-De la Medina A, Remes-Troche JM, et al. <i>Int Wound J</i> 2007; 1742-481. <sup>11</sup>	Mexico	Efficacy and Safety of Neutral pH superoxidized solution in severe diabetic foot infections
5	Dharap SB, Ghag GS, Kulkarni KP, Venkatesh V. <i>J Indian Med Assoc</i> . 2008;106(5):326, 328-30. <sup>13</sup>	India	Efficacy and Safety of Oxum in Treatment of the Venous Ulcer
6	Rahman Mohd AR, Ghani MK, Awang RR, et al. <i>The Heart Surgery Forum</i> . 2010;13(4):2009-1162. <sup>14</sup>	Malaysia	Dermacyn Irrigation in Reducing Infection of a Median Sternotomy Wound
7	Piaggese A, Goretti C, Mazzurco S, et al. <i>Int J Low Extrem Wounds</i> . 2010;9(1):10-5. <sup>15</sup>	Italy	A Randomized Controlled Trial to Examine the Efficacy and Safety of a New Super-Oxidized Solution for the Management of Wide Postsurgical Lesions of the Diabetic Foot
8	Landsman A, Blume PA, Jordan DA Jr, et al. <i>J Am Podiatr Med Assoc</i> . 2011 Nov-Dec;101(6):484-96. <sup>16</sup>	USA	An Open-label, Three-arm Pilot Study of the Safety and Efficacy of Topical Microcyn Ex Wound Care versus Oral Levofloxacin versus Combined Therapy for Mild Diabetic Foot Infections.
9	Aragón-Sánchez J, Lázaro-Martínez JL, Quintana-Marrero Y, et al. <i>Int J Low Extrem Wounds</i> . 2013 Jun;12(2):130-7. <sup>17</sup>	Spain	Super-Oxidized Solution (Dermacyn Wound Care) as Adjuvant Treatment in the Postoperative Management of Complicated Diabetic Foot Osteomyelitis: Preliminary Experience in a Specialized Department
10	Bucko AD, Draelos Z, Dubois JC, Jones TM. <i>The Dermatologist</i> 2015;23(9):113-22).	USA	A double-blind, randomized study to compare Microcyn <sup>®</sup> scar management hydrogel, K103163, and Kelo-cote scar gel for hypertrophic or keloid scars. Topical Gel for Hypertrophic and Keloid Scars.

## 2.2 | HOCL for wound management

Hypochlorous acid solution has been widely studied for the application in complex wounds, such as diabetic foot ulcers<sup>8-12</sup> and venous leg ulcers<sup>13</sup> as well as for postcoronary bypass surgery sternal wounds<sup>14</sup> and postsurgery treatment of diabetic foot ulcer patients<sup>15-17</sup> (Table 2).

Sternal wound infection is an infrequent yet potentially devastating complication following sternotomy.<sup>14</sup> A prospective,

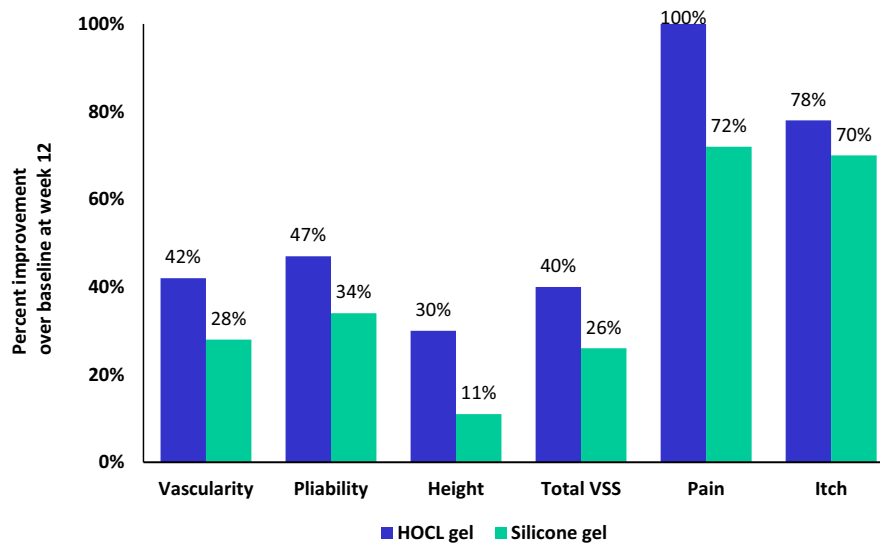
randomized clinical trial compared the effectiveness of HOCL versus povidone-iodine in reducing sternotomy wound infection in patients undergoing coronary artery bypass graft surgery.<sup>14</sup> Upon chest closure and after insertion of sternal wires, wounds were soaked for 15 minutes with either HOCL or povidone-iodine after which subcutaneous tissue and skin were closed routinely.<sup>14</sup> Of the 178 patients, n=88 treated with HOCL and n=90 patients were in the povidone-iodine group. The incidence of sternotomy wound infection was 19 cases (10.7%) of which 5 (5.7%) of these cases

**TABLE 3** Vancouver Scar Scale (VSS) efficacy results

	Hypochlorous acid(HOCL) scar gel						Silicone gel					
	Base line	Day 14	Day 28	Day 56	Day 84	Day 112	Base line	Day 14	Day 28	Day 56	Day 84	Day 112
Vascularity	1.9	1.8	1.55	1.3	1.1	1	1.78	1.53	1.44	1.28	1.28	1.11
Pliability	2.45	2.2	1.95	1.4	1.3	1.25	2.44	2.29	2.17	1.83	1.61	1.61
Height	1.85	1.8	1.6	1.4	1.3	1.25	1.56	1.53	1.39	1.39	1.39	1.22
Vancouver	6.2	5.8	5.1	4.1	3.7	3.5	5.78	5.35	5	4.5	4.28	3.94
Pain	0.45	0.05	0	0.05	0	0.05	0.39	0.29	0.22	0.06	0.11	0.11
Itch	0.9	0.7	0.4	0.5	0.2	0.2	0.94	0.47	0.33	0.22	0.28	0.17
Vancouver	6.2	5.8	5.1	4.1	3.7	3.5	5.78	5.35	5	4.5	4.28	3.94

Vancouver Scar Scale (VSS)<sup>22</sup>.

Vascularity: normal(0), pink(1), red(2), purple(3); pliability: normal(0), supple(1), yielding(2), firm(3); height: flat(0), <2 mm(1), 2-5 mm(2), >5 mm(3); pain and itch: normal(0), intermittent(1), moderate(2), severe(3).



**FIGURE 1** Improvement in appearance and symptoms of the scars<sup>22</sup>

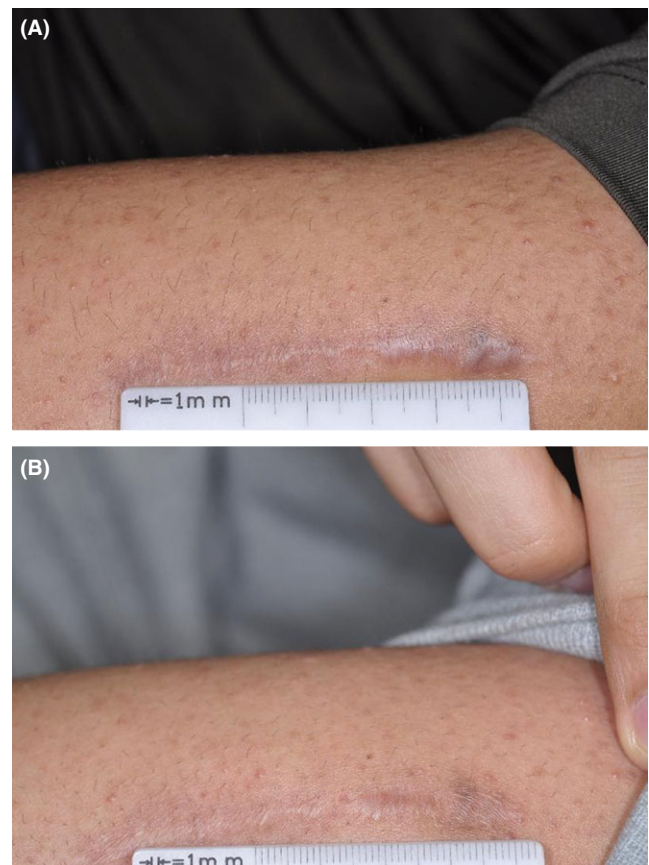
were in the HOCL treated group, and 14 (15.6%) were in the povidone-iodine group ( $P=.033$ ).<sup>14</sup>

In a randomized trial including forty patients the effectiveness and safety of using HOCL versus povidone-iodine was evaluated.<sup>15</sup> Ischemia, renal failure, bilateral lesions, or immunosuppression were considered as exclusion criteria. Patients had surgical treatment for their infected diabetic foot ulcers and were postoperatively treated with either HOCL or povidone-iodine both in adjunct to systemic antibiotic therapy and surgical debridement if needed.<sup>15</sup> Patients were followed up weekly for six months. Time to healing was significantly shorter for the HOCL treated patients (90%) than for those treated with povidone-iodine (55%;  $P<.01$ ).<sup>15</sup> The authors concluded HOCL to be safe and more effective than the previously applied standard local antiseptic.<sup>15</sup> An open-label, three-arm study of the safety and efficacy of HOCL versus oral levofloxacin versus combined therapy for mild diabetic foot Infections showed the clinical success rate to be higher for the HOCL treatment alone group (99.3%) than in the saline plus levofloxacin group (56.3%).<sup>16</sup>

In a study looking at persistent improvement of diabetic foot ulcer perfusion results from application of super-oxidized water, the author concluded that persistent improvement (upto 36 hours) of local blood flow and tissue oxygenation occurs in response to wound treatment with super-oxidized water.<sup>8</sup>  $TcPO_2$  levels increased after application. This was also evident in both type 1 and type 2 diabetics. Increases in oxygenation may lead to shorter healing time.

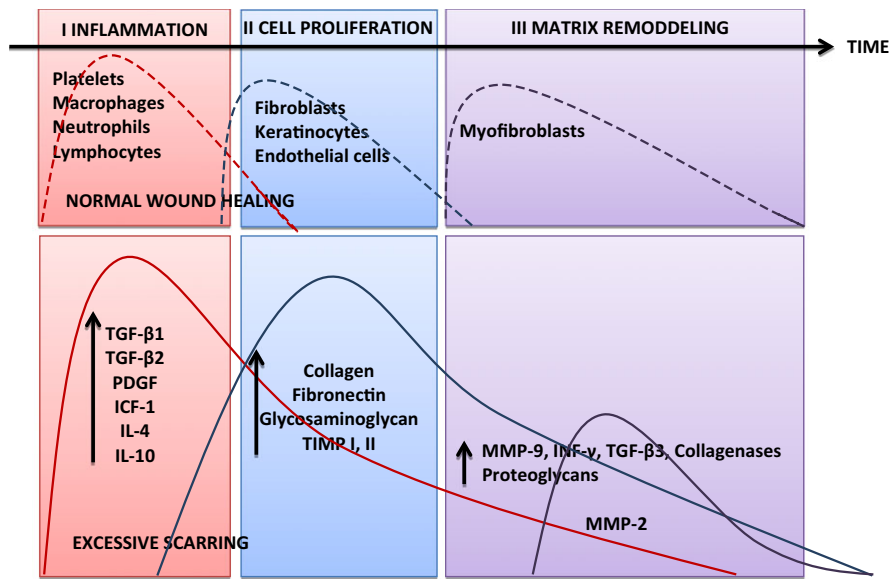
### 2.3 | Postprocedure treatment and scar prevention

An estimated 100 million people in the developed world acquire scars following elective and trauma surgery; of these patients approximately 15% have hypertrophic scarring (HTS).<sup>18</sup> Physical symptoms of scarring may include itching, stiffness, scar contractures, tenderness and pain. Psychosocial effects of unesthetic scarring may include diminished self-esteem, stigmatization, disruption of



**FIGURE 2** Patient case: Caucasian female with a 6-9 months old itchy hypertrophic scar on her left arm, which had developed after surgery. She received 8 weeks of treatment with the HOCL scar gel. At week eight, week 12, and week 16 assessment the VSS scores for vascularity, pliability, and stays height of the scar had markedly reduced as well as pruritus<sup>22</sup>

daily activities, anxiety, and depression.<sup>19</sup> HTS stays within the boundaries of the original lesion and may spontaneously regress with time, they can be classified as linear or widespread scars.<sup>19</sup> Evidence



**FIGURE 3** Differences between normal, abnormal wound healing and scar formation. Wound healing has various phases: inflammation (I), proliferation (II), and remodeling (III). Platelet degranulation activates an array of cytokines, which serve as chemotactic agents for the recruitment of cells, e.g., macrophages, neutrophils, epithelial cells, and fibroblasts. During the normal wound healing process, there is a balance between new tissue biosynthesis and degradation mediated by apoptosis and remodeling of the extra cellular matrix. A dysfunction of the underlying control mechanisms may lead to persistent inflammation, excessive collagen synthesis or deficient matrix degradation, and remodeling causing abnormal scarring.<sup>23</sup>

strongly suggests a prolonged inflammatory period may contribute to increased fibroblast activity with greater and more sustained extra cellular matrix deposition.<sup>20</sup>

Treatments for scars include surgery, laser therapy, steroid injections, and topical products, such as onion extract gel and silicone-gel. HOCL scar gel was developed to improve the appearance of scars and relieve the itching and pain associated with scars.<sup>21</sup> The hypochlorous acid in the gel is similar to the natural hypochlorous acid produced by the human body.<sup>6</sup> The HOCL gel and HOCL containing liquid products are nonirritating, nonsensitizing, and non-toxic.<sup>6</sup> In a randomized, double-blind study, the efficacy, safety, and tolerability of HOCL scar gel were compared to treatment with a 100% silicone gel, for the management of HTS or keloid scars.<sup>22</sup> The multicenter study comprised an 8-week three times daily treatment period with either HOCL gel or silicone gel as determined by randomization.<sup>22</sup> Forty-four adults with a linear or widespread HTS or keloid scar were included. The target scar resulted from a wound that had healed three to 12 months earlier and scored a minimum total on the Vancouver Scar Scale (VSS) of 3 out of 9 (Table 3). At the follow-up visits in week eight, week 12, and week 16, VSS, investigator-assessed subject global satisfaction and investigator global assessment of efficacy were scored.<sup>22</sup> Four (18%) subjects on HOCL scar gel and seven (35%) on the comparator had adverse events reported, which were all mild-to-moderate in nature and for the HOCL gel treated group not study treatment related. The scar gel performed better than the silicone gel for the management of HTS or keloid scars and both treatments were well tolerated (Figure 1).<sup>22</sup>

A typical case is presented as an illustration of the results (Figure 2).<sup>22</sup>

### 3 | DISCUSSION

Postprocedure excessive scarring may result from aberrations of the physiologic wound healing process.<sup>20,23</sup> Quality of scarring may be improved when postprocedure wound healing is effective, without complications.<sup>20,23</sup> In physiologic wound healing, a balance is achieved between new tissue biosynthesis and degradation mediated by apoptosis and remodeling of the extracellular matrix.<sup>23</sup> During excessive scar formation, a dysfunction of the underlying regulatory mechanisms may lead to persistent inflammation, excessive collagen synthesis or deficient matrix degradation and remodeling (Figure 3).<sup>20,23</sup> Scar management is challenging with many treatment options available; however, treatment results are often clinically unsatisfactory.<sup>23</sup> Topical silicone gel or silicone oil is found to be a beneficial treatment option for scarring and is recommended as part of a scar prevention and treatment regime.<sup>21,24</sup>

Hypochlorous acid products are produced during electrolysis and are classified among biocidal substances. The postprocedure regime using HOCL spray and gel are aimed at preventing infection, reducing inflammation, and promoting healing.<sup>14,15</sup>

There have been many studies evaluating the beneficial effects of HOCL solution on wound healing; however, there is limited data reviewing the effect of HOCL scar gel. However, the scar gel has demonstrated benefits over silicone gel treatment. In a randomized, double-blind study including 44 adults with a linear or widespread HTS or keloid scars, comparing HOCL scar gel to treatment with silicone gel, favorable results for HOCL gel were demonstrated.<sup>22</sup>

### 3.1 | Limitations

Large head-to-head trials against other currently used products and bacterial eradication studies are lacking. These are needed to further support the use of HOCL in postprocedure treatment and scar management.

## 4 | CONCLUSIONS

Hypochlorous acid has been shown to be an efficacious and safe therapy in postprocedure management, hypertrophic and keloid scar prevention and treatment. It is available in solution, dermal spray, and scar gel formulations. Through its potent broad spectrum antimicrobial activity and antibiofilm effects, HOCL solution has been associated with a lower risk of wound infection than povidone-iodine. It increases oxygenation at wound sites, which may improve healing time. The safety of HOCL solution has demonstrated to be comparable to that of standard local antiseptics. The scar gel formulation of HOCL has demonstrated efficacy in improving the appearance of hypertrophic and keloid scars and in relieving associated pruritus and pain. HOCL scar gel appears to be safe and well tolerated. Additional large head-to-head trials against other currently used products and bacterial eradication studies are needed to further support the use of HOCL in postprocedure treatment and scar management.

## REFERENCES

- Landa-Solis C, González-Espinosa D, Guzmán-Soriano B, et al. Microcyn™: a novel super-oxidized water with neutral pH and disinfectant activity. *J Hosp Infect.* 2005;61:291-299.
- Len SV, Hung YC, Chung D, et al. Effects of storage conditions and pH on chlorine loss in electrolyzed oxidizing (EO) water. *J Agric Food Chem.* 2002;50:209-212.
- Le Duc Q, Breetveld M, Middelkoop E, et al. A Cytotoxic analysis of antiseptic medication on skin substitutes and autograft. *Br J Dermatol.* 2007;157:1365-2133
- Medina-Tamayo J, Sánchez-Miranda E, Balleza-Tapia H, et al. Super-oxidized solution inhibits IgE-antigen-induced degranulation and cytokine release in mast cells. *Int Immunopharmacol.* 2007;7:1013-1024.
- González-Espinosa D, Pérez-Romano L, Guzmán-Soriano B, et al. Effects of pH-neutral, super-oxidized solution on human dermal fibroblasts in vitro. *Int Wound J.* 2007;4:241-250.
- Zeng XP, Tang WW, Ye GQ, et al. Studies on disinfection mechanism of electrolyzed oxidizing water on *E. coli* and *staphylococcus aureus*. *J Food Sci.* 2010;75:253-260.
- Draeos Z. Evaluation of a gel formulation of hypochlorous acid and sodium hypochlorite to reduce pruritus in mild to moderate atopic dermatitis. *Winter Clinical.* 2012;103:624-628.
- Bongiovanni CM. Nonsurgical management of chronic wounds in patients with diabetes. *J Vasc Ultrasound.* 2006;30:215-218.
- Dalla Paola L, Brocco E, Senesi A, et al. Super-oxidized solution (sos) therapy for infected diabetic foot ulcers. *Wounds.* 2006;18:262-270.
- Goretti C, Mazzurco S, Ambrosini Nobili L, et al. Clinical outcome of wide postsurgical lesions in the infected diabetic foot managed with 2 different local treatment regimens compared using quasi experimental study design: a preliminary communication. *Int J Low Extrem Wounds.* 2007;6:22-27.
- Martinez de Jezus FR, Ramos-De la Medina A, Remes-Troche JM, et al. Efficacy and safety of neutral pH superoxidized solution in severe diabetic foot infections. *Int Wound J.* 2007;1742-481.
- Hao JX, Qiu S, Li HY, et al. Roles of hydroxyl radicals in electrolyzed oxidizing water (EOW) for the inactivation of *Escherichia coli*. *Int J Food Microbiol.* 2012;155:99-104.
- Dharap SB, Ghag GS, Kulkarni KP, Venkatesh V. Efficacy and safety of oxum in treatment of the venous ulcer. *J Indian Med Assoc.* 2008;326:328-330.
- Rahman Mohd AR, Ghani MK, Awang RR, et al. Dermacyn irrigation in reducing infection of a median sternotomy wound. *Heart Surg Forum.* 2010;13:2009-1162.
- Piaggese A, Goretti C, Mazzurco S, et al. A randomized controlled trial to examine the efficacy and safety of a new super-oxidized solution for the management of wide postsurgical lesions of the diabetic foot. *Int J Low Extrem Wounds.* 2010;9:10-15.
- Landsman A, Blume PA, Jordan DA Jr, et al. An open-label, three-arm pilot study of the safety and efficacy of topical microcyn ex wound care versus oral levofloxacin versus combined therapy for mild diabetic foot infections. *J Am Podiatr Med Assoc.* 2011;101:484-496.
- Aragón-Sánchez J, Lázaro-Martínez JL, Quintana-Marrero Y, et al. Super-oxidized solution (dermacyn wound care) as adjuvant treatment in the postoperative management of complicated diabetic foot osteomyelitis: preliminary experience in a specialized department. *Int J Low Extrem Wounds.* 2013;12:130-137.
- Sund B. *New Developments in Wound Care.* vol. 86. London: PJB Publications CBS; 2000:1-255.
- Van Loey NE, Bremer M, Faber AW, et al. Itching following burns: epidemiology and predictors. *Br J Dermatol.* 2008;158:95-100.
- Sandulache VC, Parekh A, Li-Korotky H, et al. Prostaglandin E2 inhibition of keloid fibroblast migration, contraction, and transforming growth factor (TGF)-beta1-induced collagen synthesis. *Wound Repair Regen.* 2007;15:122-133.
- Gold M, McGuire M, Mustoe TA, et al. Updated international clinical recommendations on scar management: part 2—algorithms for scar prevention and treatment. *Dermatol Surg.* 2014;40:825-831.
- Bucko AD, Draeos Z, Dubois JC, Jones TM. A double-blind, randomized study to compare Microcyn® scar management hydrogel, K103163, and Kelo-cote scar gel for hypertrophic or keloid scars. Topical gel for hypertrophic and keloid scars. *Dermatologist.* 2015;23113-122.
- Gauglitz GG, Korting HC, Pavicic T, et al. Hypertrophic scarring and keloids: pathomechanisms and current and emerging treatment strategies. *Mol Med.* 2011;17:113-125.
- O'Brien L, Pandit A. Silicon gel sheeting for preventing and treating hypertrophic and keloid scars. *Cochrane Database Syst Rev.* 2006;1: CD003826.
- Sun JL, Zhang SK, Chen JY, Han BZ. Efficacy of acidic and basic electrolyzed water in eradicating *Staphylococcus aureus* biofilm. *Can J Microbiol.* 2012;58:448-454.

**How to cite this article:** Gold MH, Andriessen A, Dayan SH, Fabi S, Lorenc ZP, Henderson Berg M-H. Hypochlorous acid gel technology—its impact on postprocedure treatment and scar prevention. *J Cosmet Dermatol.* 2017;00:1–6. <https://doi.org/10.1111/jocd.12330>